

Targeted Focal (Subtotal) Therapy for Early Stage Prostate Cancer

Duke K. Bahn, MD

Prostate Institute of America (www.pioa.org)
Ventura, California
888-234-0004

Introduction:

Some observers believe that screening for PSA results in the over-diagnosis and over-treatment of prostate cancer. The justification for screening and treatment is still accepted due to the fact that almost 30,000 men die from this disease every year in the United States. The relatively slow growing nature of clinically localized prostate cancer has refuted the current established treatment options for this disease. This argument is supported by the fact that about one third men over 50 years of age will display incidental prostate cancer at autopsy, but only 10 – 16% will develop invasive prostate cancer during their life time, and only 2.5% will die from it.

Current treatment options for prostate cancer are either active surveillance or radical intervention. Radical therapy may maximize the cancer control, but with a certain degree of sexual and urinary complications which may seriously affect quality of life. Active surveillance will not impact a patient's sexual and urinary function, but it carries a psychological burden.

This paper reviews many forms of novel approaches that are called “focal therapy” or “subtotal therapy”. The goal of this approach is not only to achieve the same level of cancer control as seen in radical therapy, but also to maintain low or no complications associated with active surveillance in a selected group of men who have early organ- confined disease.

Definition of focal therapy:

There is no consensus of opinion on focal therapy. Some researchers treated only areas of known cancer while others have tried to treat the entire one half of the prostate that showed tumor involvement. There was also an attempt to treat the entire gland excluding the contralateral neurovascular

bundles. Therefore, some advocate the term “subtotal therapy” instead of “focal therapy”.

Patient Selection for Focal Cryoablation:

Optimal patient selection criteria are not clearly defined nor agreed upon in the urology field. However, it is essential that one must have unifocal or unilateral prostate cancer. Bahn used color Doppler transrectal ultrasound and staging biopsy in addition to initial extended blind biopsy that usually was performed by the patient’s physician. Some advocate more invasive saturation biopsy. It is to confirm the known tumor site but more importantly to reconfirm the absence of tumor in the other lobe. If an unexpected cancer were to be found in the other lobe by repeated biopsy, the patient is not a candidate. Low-risk prostate cancers are preferred (PSA <10, Gleason < 7, Stage <T2b, number of positive cores <4, percentage of tumor invasion < 50%), but moderate to high-risk cancers in men with medical co-morbidities can also be considered. Only unilaterality, not pre-operative PSA level or tumor differentiation, can be considered. Men with T3 stage (such as extracapsular extension or seminal vesicle invasion), as long as it is proven to be unilateral involvement, can be candidates after thorough counseling since it may carry a risk of incomplete cryoablation of tumor that may end up with nothing but a tumor debulking process.

Candidates’ prime concerns and priorities include maintaining quality of life and avoiding toxicity over cancer eradication. Candidates should have medical literacy which allows for informed consent regarding the oncologic limitations of the procedure.

Targeted Focal (Subtotal) Cryoablation:

Focal (subtotal) cryotherapy is defined as the less than complete ablation of the prostate gland with ice. A known tumor site (lobe) is aggressively treated, but the contralateral lobe of prostate tissue and surrounding structures are spared. This method offers targeted local cancer control, while preserving sexual potency and urinary continence in those whose cancer is believed to be unilateral in location.

In the PSA era, many cancers are detected at an early organ contained stage, and may be confined in one lobe of the prostate. As many as 35% of

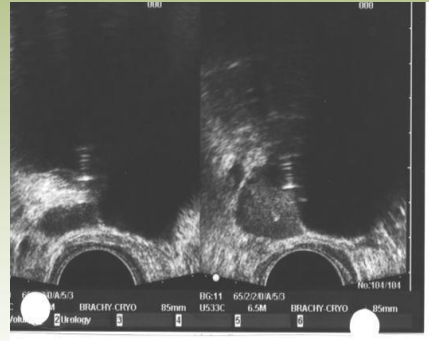
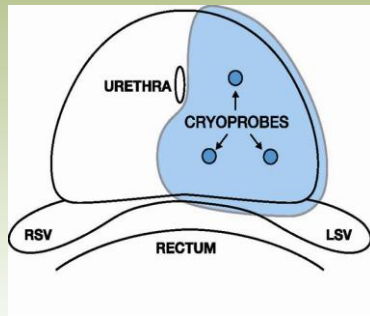
clinically localized prostate cancers are unifocal and may be candidates for focal therapy. A tumor less than 0.5cc is used as a criterion for low-volume disease; this may not require any type of intervention. Others argue that even tumors smaller than 0.5 cc may be clinically aggressive and may require intervention. It is indeed a burden to identify the proper candidates for focal therapy.

Multiple, large, single institution case studies and prospective trials have reported acceptable treatment efficacy and morbidity of total cryoablation of the prostate. The clinical outcomes after cryoablation, as measured by biochemical disease free status or negative biopsy rates, are comparable to radical prostatectomy and radiation therapy in men with intermediate and high-risk disease with significantly less morbidity.

Methods:

The cryoablation procedure uses cold temperature (ice) to ablate the tissue. The third generation technology uses argon gas for cooling and helium for warming. It consists of two freeze and thaw cycles after the placement of an FDA approved urethral warming device. Multiple cryoprobes are placed percutaneously under ultrasound guidance at strategic locations to be frozen. However, by reducing the number of cryoprobes and adjusting their placement, it is possible to perform a focal ablation that destroys only a targeted portion of the prostate and periprostatic tissue adjacent to the treatment zone. If seminal vesicle invasion was proven, it would also be frozen by advancing one of the probes towards the distal segment of the lumen of the seminal vesicle. Usually 2-4 cryoprobes are used, depending on the size of the lesion and the size of the lobe. A single probe may be placed in the contralateral lobe close to the urethra and external sphincter in case heating is necessary to protect these organs (simultaneous heating and cooling). This can be a useful technique if the prostate gland volume is small. This combination of aggressive freezing at targeted locations within the prostate while maintaining the integrity of the urethra, external sphincter, and contralateral lobe, including the neurovascular bundle, is the premise of focal cryoablation.

Focal Cryoablation



A PSA should be performed once every three months for one year and every six months thereafter. Biopsy is encouraged at 6 months, one year, two years, five years, and anytime there is a PSA elevating trend. Patients should fill out a questionnaire regarding sexual potency and urinary continence status at each visit without physician influence.

Results:

Three main papers in peer-reviewed publications on this subject were reviewed. The number of patients studied is small, only 111 subjects combined. The mean follow-up is 45 months.

Various definitions of biochemical failure have been used to evaluate the clinical outcomes. These include the ASTRO (American Society for Therapeutic Radiology Oncology) definition, which means three consecutive PSAs rising; the Phoenix definition, which is a PSA nadir plus 2; and PSA

nadir less than 50% of the pre-operative level. The biochemical disease free survival rates range between 84% and 95%.

A biopsy was performed when biochemical failure was suspected, or as protocol regardless of PSA levels. With every definition used, these three papers report fairly similar outcomes. 78 of the 111 men had undergone post-cryotherapy biopsy with cancer identified in 4 patients (5%). All except one of these residual cancers were seen in the untreated lobe.

No major complications, such as rectal injury, urethral stricture, urethral sloughing, abscess, and peri- or post-operative complications, were reported in any of these series. There was no reported case of urinary incontinence.

Results

	Onik (Urology, Dec 2007)	Bahn (Endourology, Sep 2006)	Lambert (J Urol, June 2007)
Number	N = 55	N = 31	N = 25
Follow-up	1-120 months (mean = 40m)	8-107 months (mean = 70 months)	9-72 months (mean = 28 months)
Stable PSA	95%	26/28 = 92.9%	21/25 = 84%
Biopsy: Negative	N = 26; all negative	26/27: 96.3%	22/25: 88%
Potency Preservation	44/51 = 86%	None: 3/27 = 9% Partial: 11/27 = 41% Full: 13/27 = 48% } 89%	17/24 = 71%
Age at procedure; Age at follow-up	N/A N/A	63 years (procedure) 69 years (follow-up)	68 years
Other Complications (incontinence, fistula)	None	None	None



Discussion:

Over the years, cryotherapy has evolved into an accepted cancer treatment option since the published clinical outcome results are comparable to those of external beam radiation therapy and brachytherapy. Unfortunately, in cryotherapy, as in other conventional forms of therapy, there are known potential side effects - mainly sexual dysfunction and urinary incontinence, which are serious quality of life issues. In the PSA era, most prostate cancers

are detected in the early stages, and are frequently organ confined and possibly localized in one lobe. Therefore, focal or subtotal cryotherapy is an attractive option for many men who have a small and solitary cancer that may not require aggressive therapy.

Many patients who have small cancers are advised to forgo aggressive treatment and instead undergo active surveillance management. This method is justified by the fact that prostate cancer grows slowly. However, there is always a possibility that this may result in missing a window of opportunity for a cure. Focal cryotherapy may be a good compromise for men who are not comfortable with active surveillance, but also are not comfortable with any type of radical treatment, which may risk their quality of life.

It is a burden to the practitioner to identify optimal candidates. Even though there are well-accepted criteria of low risk disease, a confirmation of unilateral or unifocal disease is far from perfect. Multiple sets of biopsies and various imaging studies including color-Doppler transrectal ultrasound may improve cancer detection, but it is still possible that we may not detect a small biologically aggressive cancer that may be spared with this type of intervention. A patient must understand this risk. Potential drawbacks to any subtotal therapy are untreated missed cancer foci and the inadequate ablation of the target tissue.

There is limited information in literature on focal cryotherapy of clinically localized prostate cancer. All of the literature is limited to a single institution's patient series, and there are no prospective randomized trial results. To date, there are three main peer-reviewed publications in this subject with small number of case studies.

The PSA failure definitions used in these three papers varied. Most of them used the ASTRO definition. One paper analyzed its data using the Phoenix definition, and also PSA nadir 50% of the pre-operative level. Regardless, the reported biochemical disease free rates were encouraging, ranging from 84% to 95%.

Based on these series, the success of the procedure is probably best defined by the follow-up biopsy. 74 patients have undergone one or more biopsies. Four positive biopsies were seen: one from the frozen lobe and three from the untreated lobes. All four patients received repeat cryoablation and

currently have no evidence of the disease. This finding may reemphasize the criticism that prostate cancer is a multi-focal disease; therefore a focal treatment may not be logical. Most patients underwent two rather extensive pre-operative biopsies to prove that their cancer was a unilateral disease. However, it is still possible that only the index tumor was detected and treated and the other microscopic or small volume tumors in the contralateral lobe were left untreated. Ohori et al published data based on 1,000 radical surgery specimens, stating that the largest focus of cancer represented 80% of all the cancer volume. More than 90% of patients with extracapsular extension were from the largest focus. The study concluded that focal ablation of the index tumor will reduce 80% of tumor burden and extracapsular extension would be controlled in more than 90%.

The reported potency preservation, with or without pharmaceutical aid, was in the range of 71% to 89%. This is better than the rate reported in the bilateral nerve sparing radical prostatectomy series, which reported a range of 21% to 63%. Focal cryotherapy is perhaps most compatible with unilateral nerve sparing radical surgery, which is associated with potency preservation rates at 13% to 64%.

There are no published reports assessing quality of life following focal cryotherapy, and only a few reports following total cryotherapy. These data compared favorably with those of other treatment modalities for prostate cancer. At one year, most men return to pre-surgical functioning status in every area with the exception of sexual function. With focal cryotherapy, it is expected that there will be improved rates of function return, and higher satisfaction.

Other Ablation Technologies

High Intensity Focused Ultrasound (HIFU)

In HIFU, an ultrasound beam is focused at a small fixed point to create high power that produces heat ranging from 80 to 100 degree C. It is proven to be lethal temperatures that will create tissue ablation. It has been applied towards organ-confined, localized prostate cancer treatment as a primary treatment or as salvage therapy after failed radiation for several years. It is not approved by FDA at this time. It is a quite popular procedure in Europe and Asia. In the US, clinical trials are underway.

HIFU is performed as an outpatient procedure, usually under spinal anesthesia. A HIFU probe is placed in the rectum and ultrasound images of the prostate are captured and treatment zone is selected. The entire prostate is treated section by section. Therefore, it could be a lengthy procedure - anywhere between 2 – 4 hours. Proper patient selection, mainly the size and configuration of the prostate, is the key to successful treatment. Many patients now undergo TURP (trans-urethral resection of prostate) immediately before HIFU to avoid urinary retention and outlet obstruction.

The published outcome data shows fairly good cancer control and acceptable rates of complication. The previous PAACT newsletter has an excellent article about HIFU by Dr. Douglas Chinn. Please refer to this article for further details.

HIFU is an appealing form of therapy for focal or subtotal therapy for prostate cancer. However, there is no clinical data in the literature to report at this time.

Radiofrequency Tumor Ablation (RFTA)

RFTA is being performed for liver, breast and kidney tumors. The role in prostate cancer is entirely experimental. RFTA transfers high-frequency monopolar and bipolar alternating currents to the targeted tissue. It initiates ionic agitation and subsequent thermal energy that leads to tissue ablation. The target temperature is approximately 100 degree C. Only limited data are reported in the literature. All patients who have underwent this procedure before radical prostatectomy did so as part of a clinical trial. RFTA showed variable degrees of tissue destruction. Results are too early to draw any conclusion. Studies are ongoing in an attempt to determine the ideal form of application in the treatment of prostate cancer. Utilizing this technique for focal therapy may be feasible, but not considered for the near future.

Microwave Thermal Ablation (MTA)

The MTA technique for prostate cancer treatment uses a microwave antenna that is placed in the prostatic urethra. The goal is to heat the prostate to 55 – 70 degree C to ablate the tissue. Early clinical experiences are with failed external radiation therapy patients. One study reported about a 70% negative biopsy rate at 6 months after, but only 52% patients had a PSA level less than 0.5 ng/mL. MTA has been used in conjunction with external beam therapy

for the patients with locally advanced prostate cancer. Data are still early and sporadic. Using this technology in focal therapy may be feasible in the future, but not any time soon.

Photodynamic Therapy (PDT) or Vascular-Targeted Photodynamic Therapy (VPD)

This technique describes the destruction of a target tissue via the administration of an inactive, light sensitive agent (photosensitizer) and the local application of light in the presence of oxygen. The photosensitizer absorbs a laser light and transfers this energy to the tissues, creating cell destruction. One recently developed photosensitizer has a tendency of staying within the tumor vascular network. Due to this reason, when PDT is applied, extensive vascular damage is created that leads to tissue necrosis. It is referred to “Vascular-Targeted PDT.” One small study of 13 patients who had salvage VPD reported 8/13 biopsy negative at 6 months. Two patients experienced urethra-rectal fistulae. Again, this technology can be potentially utilized in focal therapy in the future, but it has a long way to go.

Focal Brachytherapy

Brachytherapy has been a well established modality for localized prostate cancer for many years with a proven record. It is currently being used in breast cancer therapy. I strongly believe it can be modified for focal or hemi-ablation therapy for prostate cancer. Surprisingly, there were no reports found in the literature. Most definitely, high-dose rates of brachytherapy could be applied for focal or subtotal therapy.

Nanotech-Laser Treatment

This technology uses nanoparticles, such as gold coated silica nanoshells or carbon nanotubes since they absorb near-infrared light waves and release excess energy in the form of heat. Researchers were able to generate heat up to 70 degree C, enough for tissue ablation. Most information is based on animal models and clinical application is in the planning stages. Depending on future development, it can be utilized in the form of focal therapy in prostate cancer.

Conclusion:

Focal cryosurgery represents a modification of the whole gland approach and appears to offer acceptable oncologic efficacy with reduced treatment related adverse events. The risk of incomplete eradication of cancer is likely to be small in an appropriately selected population of men with low volume and low risk prostate cancer. It is precisely this population of men who are presently confounded by the choice between active surveillance and a more complex whole-gland treatment. There are other competing technologies that can be applied to focal or subtotal therapy. Some of them are not ready for clinical use, but are intriguing. The most important component in any focal therapy is the precise imaging. Without clear identification of the tumor, its location and stage of the disease, focal therapy can be a blind approach and the final clinical outcome may be less than optimal, with unnecessary complications. Efforts to improve prostatic imaging, such as high resolution color-Doppler ultrasound, application of ultrasound contrast materials, high strength MRI including dynamic contrast scan, usage of paramagnetic nanoparticle as a MRI contrast agent, improved spectroscopy, and all other new developments should be encouraged.

Suggested Reading

1. Bahn DK, et al: Focal prostate cryoablation: Initial results show cancer control and potency preservation. *J of Endourology*. Vol 20, No 9, p688-692, Sept. 2006
2. Onik G, et al: "Male lumpectomy": focal therapy for prostate cancer using cryoablation. *Urology*. 2007 dec;70(suppl):16-21
3. Jones JS. Et al: Focal or subtotal therapy for early stage prostate cancer. *Current treatment options in oncology*. Springer, Boston. Vol 8, No 3, June 2007
4. Gillett MD et al: Tissue ablation technologies for localized prostate cancer. *Mayo Clin Proc* Dec 2004;79(12):1546-1555
5. Polascik TJ et al: Focal therapy for prostate cancer. *Current opinion in urology* 2008, 18:269-274
6. Lambert EH et al: Focal cryosurgery: Encouraging health outcomes for unifocal prostate cancer. *Urology*. 69(6), 1117-1120
7. Bahn DK et al: Focal cryoablation of prostate: A review. *The ScientificWorld Journal* (2008) 8, 486-491

